

Swift Resolution of a Peristomal Skin Complication Utilising a Ceramide Infused Barrier

Emma Ludlow, RN, STN, Auckland, New Zealand

C

Abstract

People with ostomies can face a variety of challenges. Many of these challenges might be avoided with the correct initial product selection that is based more on evidence than on experience. This case explores the set of challenges a patient experienced that appeared mainly due to using ostomy products lacking both fit and formulation properties to manage his stoma.

Relevant Medical History

Mr. B (initial changed to protect privacy) is a sixty-one-year-old male originally from Samoa. In 2004, he was diagnosed with a gastrointestinal stromal tumour (GIST) and underwent his first surgical procedure for removal of the tumour and formation of a temporary ileostomy. GISTs are soft tissue sarcomas that may be found any part of the digestive system but most frequently in stomach and small intestine.¹ Most GISTs remain 'silent' until reaching a large size and symptoms can vary according to location and size.² In the case of Mr. B, his tumour was assumed to be in the small intestine. GISTs can develop in people of all ages, but most commonly between age 50 and 70, and almost never occurring before age 40.^{1,2}

Later, his ileostomy was reversed, however the GIST spread to his rectum, and in 2007 after refusing an abdomino-perineal resection (APR) he required further surgical excision with another temporary ileostomy formed that was also reversed at a later date. Metastatic spread occurs often and usually 10-15 years after original surgery.² However, his symptoms worsened at a faster pace, and he underwent an APR with vertical rectus abdominis myocutaneous flap (VRAM) in 2012 and formation of a permanent colostomy. The VRAM flap is preferred for pelvic reconstruction as it is a combination myocutaneous flap comprised of three layers: skin, subcutaneous fat, and muscle. This triple-layer anatomy makes the VRAM flap durable, and the flap can be used to cover skin defects.³

Background

Originally, Mr. B was managed at another district health board (DHB) further south in New Zealand, so access to some of his information proved challenging. He spoke little to no English and communication was mainly through his wife. Additionally, to complicate things further, he previously had a cerebrovascular accident (CVA) in 2017 that left him with expressive dysphasia but no other residual deficits such as motor skill challenges. He was still ambulatory and independent in self-care. However, this expressive dysphasia often left him feeling frustrated, resulting in him becoming non-conversant with his wife.

He also suffered with chronic renal failure (his creatinine was 211). Of note, people of all genders and ages suffering with chronic renal failure, are also prone to pruritis (chronic itching).⁴ He was also obese with a body mass index of 40. Generally, a healthy BMI is between 18.5 and 24.9, however this may be higher in people of Polynesian origin.⁵

Lastly, he had recurrence of tumour locally in the perineal region requiring treatment in Auckland at our hospital. This required both he and his wife move into emergency accommodation near our hospital.

Skin Profile

At initial review, his skin had multiple broken areas that appeared visually reddened and inflamed fully circumferential to the stoma. The affected skin was only directly under the barrier footprint and did not extend beyond the skin barrier edges. This type of skin reaction was determined to be a Peristomal Medical Adhesive Related Skin Injury (PMARSI) as he was not experiencing leakages. PMARSI differs from irritant contact dermatitis where skin is exposed to stoma effluent. Here, the issue is related rather to the exposure of skin to an adhesive.⁶

continued over page




Figure 1 CeraPlus™ one-piece pouching system with flat cut-to-fit skin barrier.

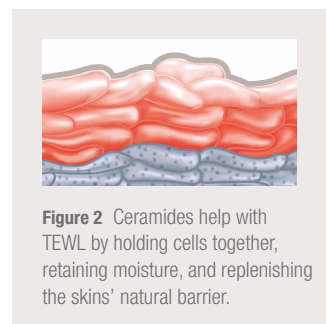


Figure 2 Ceramides help with TEWL by holding cells together, retaining moisture, and replenishing the skin's natural barrier.

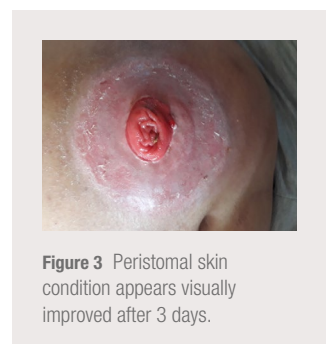

Figure 3 Peristomal skin condition appears visually improved after 3 days.

LEVEL OF EVIDENCE - CASE STUDY

Swift Resolution of a Peristomal Skin Complication Utilising a Ceramide Infused Barrier

His wife reported that he had been tried three different brands of ostomy products with poor success. She said he expressed that his skin was very itchy and painful. As described, his history was vague on some of the aspects of his care, but it appeared they may have also tried cortico-steroid creams, and other topical agents such as wipes without success. His wife reported that he could guess when his stoma would be active and would often leave the pouching system off and his skin exposed to air to gain relief.

Products Used & Outcomes

A skin barrier infused with ceramide, the CeraPlus™ skin barrier* was chosen. (See Figure 1) Ceramides are naturally occurring waxy lipids that occur naturally in human skin that help reduce trans-epidermal water loss (TEWL) which is water loss through the stratum corneum.⁷ (See Figure 2) When peristomal skin is healthy, skin keeps moisture in and irritants out. The product type chosen was a flat, cut-to-fit one-piece closed pouching system. While Mr. B had no dexterity issues, his wife would cut the barriers to the desired template size and shape as instructed. The output from his stoma was regular and thusly, he only needed to change the pouching system once per day. Within only three days, his skin appeared markedly improved visually. (See Figure 3) It was unfortunate a 'before' image was not captured to clearly demonstrate how severely compromised his skin had been. No accessories or other materials were required.

Mr. B (via his wife) expressed how happy they were with the results. He reported a quick resolution in his itching and discomfort, and she commented how much healthier his peristomal skin appeared visually. They are reporting that his skin continues to improve.

Conclusion

Clearly, not all skin barrier adhesives are the same. Products are often chosen based on style when the more important consideration is the critical goal of proactively attaining and maintaining healthy peristomal skin. Without healthy peristomal skin, other product features become irrelevant. This was his fourth pouching system evaluated and the only one to provide Mr. B with rapid resolution of his skin condition and itching. CeraPlus™ skin barriers through their fit and formulation attributes, may help assist patients in the prevention of peristomal skin complications such as PMARSI and TEWL from occurring.



To learn more
about CeraPlus™
Products, click here
or scan the QR code



To visit the
Hollister website,
click here or scan
the QR code



To visit the Hollister
Clinical Education
Website, click here
or scan the QR code

References

1. Mayo Clinic 2020, 'Gastrointestinal stromal tumor (GIST)', <https://www.mayoclinic.org/diseases-conditions/gastrointestinal-stromal-tumors/cdc-20387715>, Accessed March 2020.
2. Xiaohui, Z & Changjun, Y 2012, 'Gastrointestinal stromal tumor', *Journal of Gastrointestinal Oncology*, vol. 3, no. 3, pp. 189–208.
3. Sagebiel, TL, Faria, SC, Balachandran, A, Sacks, JM, You, YN & Bhosale, PR 2011, 'Pelvic reconstruction with omental and VRAM flaps: Anatomy, surgical technique, normal postoperative findings, and complications', *RadioGraphics*, vol. 31, no. 7.
4. Vyas, R 2010, 'Uraemic pruritus', *DermNet NZ*, <https://dermnetnz.org/topics/uraemic-pruritus/>, Accessed March 2020.
5. Australian Government, Department of Health, 'Body Mass Index', <http://healthyweight.health.gov.au/wps/portal/Home/get-started/are-you-a-healthy-weight/bmi>, Accessed March 2020.
6. Kimberly, LeBlanc, K, Whiteley, I, McNichol, L, Salvadalena, G & Gray, M 2019, 'Peristomal Medical Adhesive-Related Skin Injury - Results of an international consensus meeting', *Journal of Wound Ostomy & Continence Nursing*, vol. 46, no. 2, pp. 125-136.
7. Grove G, Houser T, Sibbald, G & Salvadalena, G 2019, 'Measuring epidermal effects of ostomy skin barriers', *Journal of Skin Research Technology*, vol. 25, no. 2, pp: 179-186.



*Contains the Remois Technology of Alcare Co., Ltd.

Prior to use, be sure to read the Instructions for Use for information regarding Intended Use, Contraindications, Warnings, Precautions, and Instructions.

Disclaimer: This case study represents this nurse's experience in using the CeraPlus™ skin barriers with the named patient, the exact results and experience will be unique and individual to each person.

Hollister, the Hollister logo, the Hollister Education logo and CeraPlus are trademarks of Hollister Incorporated. All other trademarks and copyrights are the property of their respective owners. Not all products are CE marked.

© 2023 Hollister Incorporated.



Hollister Incorporated
2000 Hollister Drive,
Libertyville, Illinois 60048

www.hollister.com