

Using Latest Evidence to Proactively Match the Characteristics of the Convex Skin Barrier to Those of the Patient

Sheryl Waye, RN, STN, Queensland, Australia

I

Abstract

“Knowledge is power? No. Knowledge on its own is nothing, but the application of useful knowledge, now that is powerful.” – Rob Liano.

This case study has provided a tangible opportunity to apply some new theory that we found exciting to learn and adopt into clinical practice at our hospital. Until very recently, confusion around convex product use has been made all the more challenging with differing descriptors used by both manufacturers^{1,4,5} and frequently a clinician’s subjective experiences. This recent publication has greatly assisted in clarifying some of the perceptions regarding product features that were both known and unknown to us. Importantly, it provided clinical application statements that are highly relevant to the practice of stoma care.

Patient Relevant Background & Surgical History

Mr. W was a middle-aged male who presented to our hospital’s emergency department after experiencing significant alterations in his bowel habits over the period of a month. Additionally, he had become quite cachectic and undergone some significant weight loss. Cachexia is characterised by a dramatic loss of skeletal muscle mass and often accompanied by substantial weight loss, where the body breaks down muscle and adipose tissue, which stores fat. It occurs in many cancers, usually at the advanced stages of disease and seen in certain subset of cancers including that of colorectal cancer.²

Mr. W underwent a CT scan (computerised axial tomography) which confirmed a right abdominal and pelvic mass associated with the sigmoid colon, with fistula formation involving his bladder. Subsequently he proceeded to have a biopsy which confirmed the presumed diagnosis of cancer. His primary cancer was a sigmoid adenocarcinoma. As a matter of urgency, Mr. W was taken to the operating theatre to undergo an open, high anterior resection, small bowel resection with formation of a loop ileostomy and a partial cystectomy.

Early on, Mr. W experienced few if any challenges with his well-spouted loop ileostomy and learned to manage his stoma care quite well. His peristomal planes were only slightly irregular when he was sitting, and he had a relatively soft abdominal tone. His output while liquid, was relatively thick and expected to thicken further as it was established. (See Figure 1) However, his recovery was complicated by a post-operative bladder leak which was managed prior to discharge. He was discharged to his home with a two-piece soft convexity product, as there were concerns for potential leakage regarding the semi-liquid nature of his output, despite how well-spouted his loop ileostomy was. (See Figure 2) This product had the additional benefit of having a skin barrier infused with ceramide, the Hollister CeraPlus™ skin barrier*. The CeraPlus product portfolio has robust evidence illustrating its support in helping maintain healthy peristomal skin. This is a core goal of care for managing our patients. Thus, there was a proactive deliberation to choose a skin health supporting product with convexity from the outset based on recommendations from a consensus panel that liquid output is a clinical consideration for using convexity of some form.³

Challenges

After approximately three months post surgery, he was readmitted to our hospital with high output and dehydration. He had been experiencing chronic challenges from leakage and the stomal therapy nurse (STN) was asked to review his situation. He had been undergoing adjuvant chemotherapy after discharge before his situation deteriorated. The patient reported that the incidences of leakage had been increasing since discharge to multiple times a day over the last week.

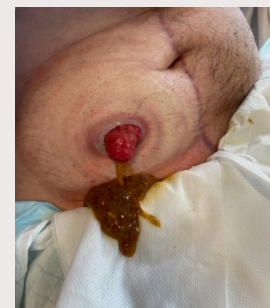


Figure 1 Thick discharge from his ileostomy.

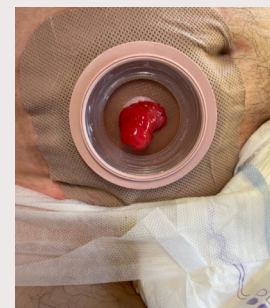


Figure 2 Two-piece soft convex skin barrier in place. Well-spouted stoma.

LEVEL OF EVIDENCE - CASE STUDY

Using Latest Evidence to Proactively Match the Characteristics of the Convex Skin Barrier to Those of the Patient

What had changed since his return to home was the development of high output draining from his ileostomy. His stoma was discharging up to six litres per day and he had become severely dehydrated.

Coupled with his chemotherapy, there are reports that there can be a three-fold increase in ileostomy output between post-operative discharge and hospital readmission.⁴ The potential for kidney damage resulting from such a scenario is high and correct rehydration and stoma management is important.⁴

Nursing Interventions

Based on the change in his circumstances, his pouching system needed review to meet his changed needs. Recently, additional information to assist clinicians in selecting the right convexity feature based on a characteristic or a set of characteristics has been published. In this article, five (5) characteristics of convex products were identified and defined, and clinical implications & application statements were developed.⁵ Using this new source of knowledge helped enable the STN to select the right product for this patient. Previously, it was understood that while convexity was well-used and well-regarded, it was not clear how and why it worked in some clinical situations. This framework can now be used when reviewing our patients for the use of convex products.

Depth was our first consideration. His stoma was well-protruding, and the recommendations are that the depth used should be just enough to afford a secure skin seal.⁵ Excessive depth was not required. This narrowed convex choices in this instance. As mentioned previously, Mr. W's peristomal planes had slight irregularities that were more distal to his stoma. As such tension location, our second consideration, was of high consideration to flatten areas that might impinge of the overall skin seal by causing challenges on movement. Positioning the apex of the convex barrier further out from the stoma can help flatten creases and folds that could interfere with a secure seal. As such, a cut-to-fit skin barrier, one size up from what the measuring guide indicates, can help provide the greatest tension away from the stoma to help flatten the peristomal skin for a secure seal.⁵

Compressibility had now become an interesting consideration. His previous system was soft, with tension location further afield as well. However, he was experiencing leakage. Now with his changed medical circumstances, he required something less compressible. Noting his soft abdominal tone, the recommendations are that he may now require a less compressible convex skin barrier to provide adequate support around the stoma.^{4,5} Interestingly, his previous soft convex product was deeper than the suggested firm convex under assessment. However, it was noted in the journal article that the compressibility of the convex dome influences the depth of convexity.⁵ As such, the firmer type of product was now less deep, yet provided the support and secure skin seal now required to manage the changed nature of his output.

Overall, he required some degree flexibility in his product due to his high activity levels, yet the dome need to be somewhat firmer to manage his peristomal contours. The overall design of the product with the adhesive border and floating flange contributed to a more flexible product that still provided the level of support through some rigidity where it was required, and this proved to be the solution he required. Slope is the last consideration, and this was not seen as a critical consideration in this case given his peristomal contours and the stomal protrusion.

Lastly however, was the consideration of his pouch. With high volumes of output that was essentially all liquid, he required a high output pouch. (See Figure 3) This enabled the capture of excessive fluid for short periods, for example walking, and the easy connection to a secondary collection system for drainage. (See Figure 4) This new system was easy for both ward staff and patient management throughout his readmission. The plan was to have his colorectal assessment and early stoma reversal.

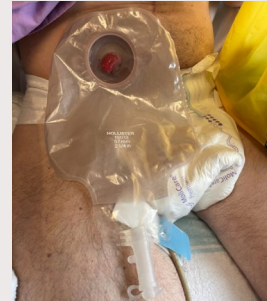

Figure 3 Thick discharge from his ileostomy.

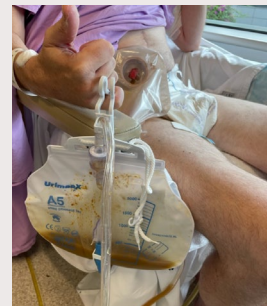

Figure 4 Two-piece soft convex skin barrier in place. Not well-protruding stoma.

LEVEL OF EVIDENCE - CASE STUDY

Using Latest Evidence to Proactively Match the Characteristics of the Convex Skin Barrier to Those of the Patient

Patient Outcomes

Mr. W was able to easily manage this system as it was so similar to the one he had been discharge home with in the first instance. Teaching time for this process was reduced as a result. However additional education regarding vigilance around maintaining his skin health due to the new nature of his output was important. Additionally, education about the warning signs of dehydration and management methods was also crucial for his overall wellbeing. Despite his high output stoma, his peristomal skin remained visually healthy with no observable skin issues with this revised system until his stoma was ultimately reversed.

Conclusion

Obtaining knowledge is always important. However, more important is embracing that knowledge and applying it. This can lead to optimised outcomes for our patients and reduce some of the confusion regarding product selection. Convexity products have been available for some time now, however, we have had little understanding of the dynamics and characteristics of the differing types of convexity and their application. This new nomenclature now provides stoma care nurses with a more consistent means to communicate with each other their patient management techniques and to also document them. This is an important consideration for future research in stoma care. It is hoped that these descriptors and measurement are also adopted by ostomy product manufacturers to ensure consistency of labelling, and to remove some of the subjectivity often associated with product selection.



To learn more about CeraPlus™ Products, click here or scan the QR code



To visit the Hollister website, click here or scan the QR code



To visit the Hollister Clinical Education Website, click here or scan the QR code

References

1. Hoeflok, J, Kittscha, J & Purnell, P 2012, 'Use of convexity in pouching - A comprehensive review', *Journal Wound Ostomy Continence Nursing*, vol. 40, no. 5, pp.506-512.
2. NIH, 2011 'Tackling the Conundrum of Cachexia in Cancer', *The National Cancer Institute*, <https://www.cancer.gov/about-cancer/treatment/research/cachexia>, Accessed April 2022.
3. Hoeflok, J, Salvadalena, S, Pridham, S, Droste, W, McNichol, L & Gray, M 2017, 'Use of convexity in ostomy care – Results of an international consensus meeting', *Journal Wound Ostomy Continence Nursing*, vol. 44, no. 1, pp. 55-62.
4. Nasser, R, Parrish, CR, & Bridges, M, 2019, 'High output ileostomies: The stakes are higher than the output', *Practical Gastroenterology*, vol. 43, no. 9, pp. 20-33.
5. Cobb, T, Depaive, Y, Quigley, M, McNichol, L & Smitka, K 2021, 'Characteristics of Convex Skin Barriers and Clinical Application - Results of an International Consensus Panel', *Journal Wound Ostomy Continence Nursing*, vol. 48, no. 6, pp. 524-532.



*Contains the Remois Technology of Alcare Co., Ltd.

Prior to use, be sure to read the Instructions for Use for information regarding Intended Use, Contraindications, Warnings, Precautions, and Instructions.

Disclaimer: This case study represents this nurse's experience in using the CeraPlus skin barriers with the named patient, the exact results and experience will be unique and individual to each person.

Hollister, the Hollister logo, the Hollister Education logo and CeraPlus are trademarks of Hollister Incorporated. All other trademarks and copyrights are the property of their respective owners. Not all products are CE marked.

© 2023 Hollister Incorporated.



Hollister Incorporated
2000 Hollister Drive,
Libertyville, Illinois 60048

www.hollister.com